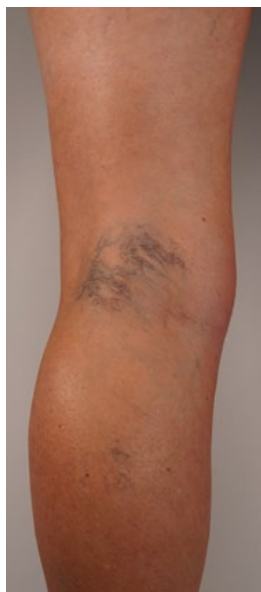

When to refer

Dr Haroun Gajraj discusses when to refer leg spider veins to a vascular specialist

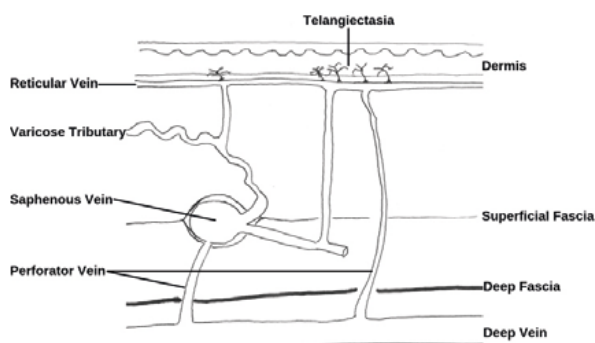
Telangiectasia are called spider veins and thread veins by the public: small, superficial veins in the dermis of the skin, found in clusters on the legs. Reticular veins are usually referred to as blue veins and they are situated slightly deeper at the junction of the dermis and subcutis. Nearly half the adult population has blue leg veins and telangiectasia and requests for treatment are rising quickly as the public becomes aware that treatment by microsclerotherapy is safe, effective and available privately (Figure 1).



In most cases, people are concerned by the appearance of their thread veins and blue veins, but telangiectasias and reticular veins may cause symptoms such as ache, itch, throbbing and cramps. Leg telangiectasias and reticular veins can be a sign of superficial venous reflux which may benefit from investigation by duplex ultrasound and treatment in order to mitigate the risks of venous complications such as superficial venous thrombosis, venous eczema and venous ulceration. For

Figure 1: Idiopathic popliteal fossa leg telangiectasias suitable for microsclerotherapy

this reason, it is important that patients with telangiectasia and reticular veins are assessed appropriately prior to microsclerotherapy (Figure 2).



Based on Somjen GM et al 1993

Figure 2: Schematic of connections of telangiectasia and reticular veins, showing that these may be secondary to venous reflux

Microsclerotherapy is safe and effective. It is widely practiced around the world. For selected patients, in an appropriate clinical setting, with sufficient training and with regular practice, microsclerotherapy can be undertaken by doctors and nurses from a wide range of specialties and backgrounds.

Selecting people for microsclerotherapy and identifying those who might benefit from a referral for a specialist vascular opinion are clinical management decisions based on a history, examination and Continuous Wave Doppler screening test (Fig 3).

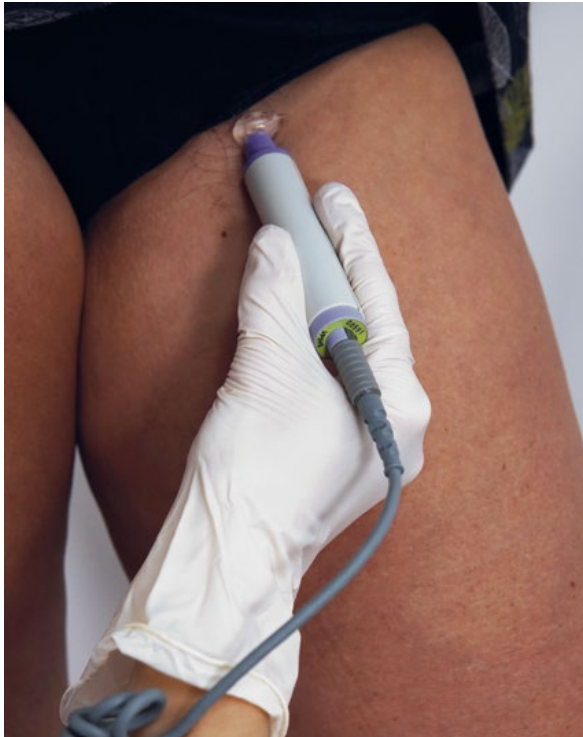

Figure 3: CWD for detecting saphenofemoral reflux

INCLUSION CRITERIA

- Healthy patients without significant comorbidity
- Absence of varicose veins
- Leg telangiectasia and reticular veins only
- Healthy skin with no pigmentation or signs of chronic venous insufficiency (including severe ankle telangiectasias and reticular veins - corona phlebectasia)
- No major swelling
- No contraindications

NOTES

- BMI >30 is a major risk factor in line with NICE guidelines [nice.org.uk/guidance/ng89/resources/department-of-health-vte-risk-assessment-tool-pdf-4787149213](https://www.nice.org.uk/guidance/ng89/resources/department-of-health-vte-risk-assessment-tool-pdf-4787149213)
- My recommendation is that those who plan air travel > eight hours or a journey of any type >12 hours are at increased risk of DVT. This is in line with NICE guidance [cks.nice.org.uk/dvt-prevention-for-travellers#!scenario](https://www.nice.org.uk/dvt-prevention-for-travellers#!scenario)

There is a four-fold increase in risk for air-travel over eight hours and the risk increases markedly for journeys in excess of 12 hours.

INITIAL EXAMINATION

A thorough general medical history should be taken and, in addition, symptoms of venous disease such as ache, throbbing and swelling should be sought. Graduated compression hosiery is frequently prescribed after sclerotherapy and therefore patients should be asked

about symptoms of vascular disease, such as intermittent claudication, which may be a contraindication to compression.

Patients should be given privacy to undress and the legs should be examined in good light, with the patient standing and the legs exposed from the groin to the feet. The patient should stand for at least two to three minutes to allow varicose veins (if present) to fill. There is a risk of syncope during the examination, so I ask the patient to lean against the treatment couch.

Signs of underlying venous disease should be sought. You must be able to see the entire leg, not just the veins that concern the patient.

Check and record the following details:

- History of ache, throbbing and swelling
- History of claudication or cardiovascular disease
- Past history of vein treatments and thromboembolism
- Skin colour, warmth and texture
- Any abnormal scars or pigmentation/marks
- Types of vein that are visible
- Feel for varicosities
- Identify and discuss with the patient those veins that concern him or her most and consider your treatment plan.

DOPPLER ASSESSMENT

Reflux (abnormal reverse flow) may be confirmed by Continuous Wave Doppler (CWD) or Colour Duplex Imaging (CDI). CWD is a screening test that I recommend as a minimum to check for superficial venous reflux. CDI is the gold standard diagnostic test for venous disease. CDI may be indicated by the clinical history or examination or by a positive CWD test. I recommend that those who undertake microsclerotherapy establish a referral pathway for CDI and to a vascular specialist for a second opinion when indicated.

“Nearly half the adult population has blue leg veins and telangiectasia and requests for treatment are rising”

REFERRAL FOR COLOUR DUPLEX IMAGING

It is generally appropriate to request CDI for any of the following type of patient:

- Has symptoms suggestive of venous disease such as ache, throbbing and swelling; worse with standing, relieved by elevation
- Has CWD evidence venous insufficiency (at saphenofemoral or saphenopopliteal junctions or in a palpable vein) >

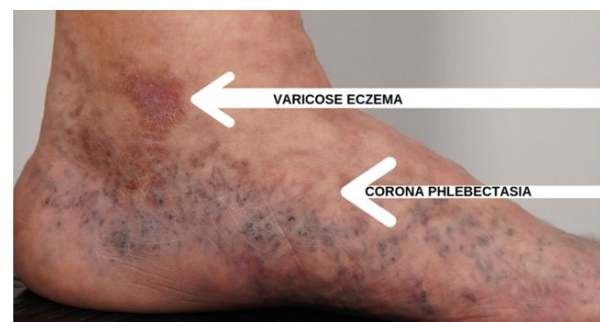


Figure 4: Corona phlebectasia and skin changes indicating need for CDI

- Has palpable veins larger than 5mm in diameter
- Has corona phlebectasia or skin changes (Fig 4).

CDI examinations are not routinely performed on patients who present simply for spider veins and small reticular veins.

If there are concerns about the patient's arterial circulation, examine the patient supine on the couch, palpate foot pulses and perform an arterial Doppler examination (Fig 5). Consider referring patients with arterial disease and offer life-style advice (smoking cessation for example).

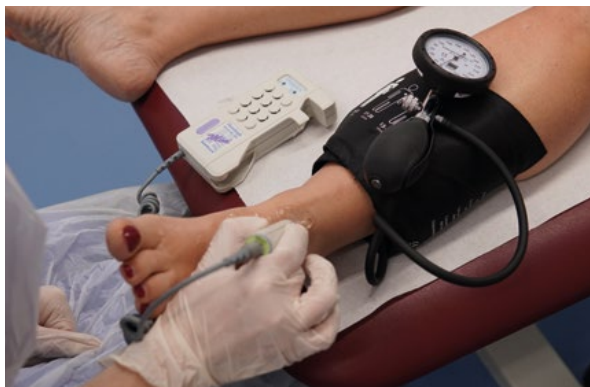

Figure 5: Assessment of arterial circulation by Doppler Pressure Indices

ABSOLUTE CONTRAINDICATIONS

In my opinion, the following are absolute contraindications to the treatment of telangiectasia and venulectasia for cosmetic reasons:

- Pregnancy and breast-feeding mothers*
- Generalised systemic disease such as cardiac, renal, hepatic, pulmonary and collagen diseases and malignancies
- Severe rheumatoid arthritis or osteoarthritis or indeed any disease which significantly interferes with the patient's mobility and which may render the patient susceptible to deep vein thrombosis
- History of deep vein thrombosis
- Acute febrile illness
- Allergy to sclerosing agents or any other constituent of the solution
- Severe atopy such as bronchial asthma, severe skin eczematous conditions
- Severe Lymphoedema
- Thrombophilia clotting disorders
- Immunodeficiency or use of immuno-suppressants such as steroids
- Recurrent cellulitis.

*Pregnancy has a variable effect upon lower extremity varicose veins and telangiectasias. In general, with repeated pregnancies, telangiectasias and varicose veins appear earlier and are more severe. This process peaks at the third pregnancy. It is wise to wait at least six months postpartum

before administering treatment. Veins that appear or worsen during pregnancy may spontaneously resolve.

RELATIVE CONTRAINDICATIONS

The following in my opinion are relative contraindications and, in such cases, sclerotherapy should only be undertaken after a risk assessment by very experienced practitioners and after careful consultation with the patient:

- Elderly and sedentary patients (older than 80 years of age)
- Obesity¹
- Patients with arterial insufficiency (who may not tolerate compression hosiery and who may have delayed healing if they develop skin necrosis)
- Patients with associated varicose veins or skin changes associated with venous disease; or patients with a positive CWD screening test
- Diabetes (increased prevalence of arterial disease, neuropathy and poor wound healing)
- Patients on anticoagulants
- Recent or upcoming long-haul flights²
- Patients with unrealistic expectations (consider body-dysmorphia).

Provided patients are carefully selected, microsclerotherapy is the most effective treatment for leg telangiectasias. Healthcare professionals who provide this treatment must be clear when it is appropriate to decline treatment and when to consider referral to a venous or vascular specialist. I strongly recommend that those who undertake microsclerotherapy establish referral pathways for Colour Duplex Imaging and for a second opinion both before treatment and in the event of an unexpected complication such as matting, ulceration, or resistance to sclerotherapy.

SUMMARY: REASONS FOR REFERRAL

- Referral for Colour Duplex Imaging as listed above
- Symptoms or signs of arterial disease
- Failure of microsclerotherapy to improve telangiectasia (might there be superficial venous reflux?)
- Severe neotelangiectasias (sometimes called "matting") after microsclerotherapy (might there be superficial venous reflux?)
- Complications such as skin ulceration (for help in their management) **AM**

FURTHER READING

- 'Sclerotherapy: Treatment of Varicose and Telangiectatic Leg Veins'. Mitchel P Goldman and Robert A Weiss. 6th Edition © 2017 Elsevier Inc
- 'Somjen GM. Anatomy of the Superficial Venous System'. *Dermatol Surg* 1995; 21: 35-45
- British Association of Sclerotherapists <https://www.bassclerotherapy.com/articles/>



Dr Haroun Gajraj is a phlebologist based in Dorset. He is the medical director of the VeinCare Centre, Responsible Officer for the GMC, specialist adviser for NICE and sits on the board of the British Association of Sclerotherapists. The VeinCare Centre is regulated by the Care Quality Commission and is a Designated Body with the GMC. In 2019, The VeinCare Centre won business awards for "Customer Care" and "Online Engagement".