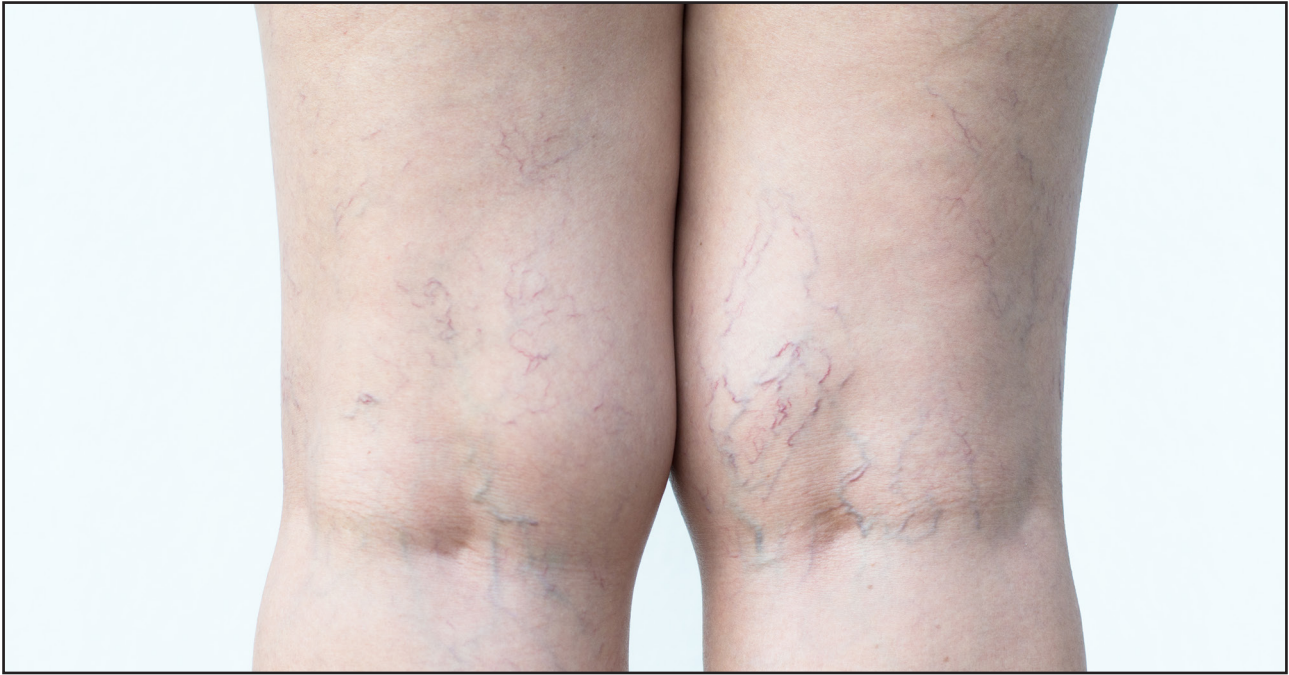



Ton Blackmarine/Shutterstock

## THE SCLEROSANT DRUG AETHOXYSKLEROL

President of the British Association of Sclerotherapists, Mr Philip Coleridge-Smith discusses the 'newest kid on the block'

Sclerotherapists the world over have used Aethoxysklerol over many years to treat varicose veins and thread veins on the legs.

This drug, which is also known as Lauromacrogol 400 and Polidocanol, has been in use as a sclerosant drug since 1950 but was not licensed for use in the UK until 24th December 2018 when Ferndale Pharmaceuticals Ltd were awarded a marketing authorisation by the Medicines and Healthcare Products Regulatory Agency (MHRA).

Before this, the only other licensed drug was sodium tetradecyl sulphate (Fibrovein, STD Pharmaceuticals Ltd).

### Mechanism of action

Both of these drugs are detergents and treat veins by destroying the endothelial cells lining the veins by dissolving the membrane of the cells which are made of phospholipid. Just like the detergents used in washing-up lipid, these sclerosants will dissolve fat (lipid). The endothelial cells are instantly destroyed, and this is followed by blood sticking to

the vein wall and clotting. The vein is blocked by thrombus which leads to permanent destruction of the vein if the treatment is done correctly. The same mechanism leads to successful treatment of any vein between large saphenous varices and tiny thread veins, also known as telangiectases or spider veins.

### Treatment of thread veins and reticular veins

The strength of treatment varies according to the size of the vein. This is summarised in the *European Consensus on Sclerotherapy in chronic venous disorders* (Rabe E et al, *Phlebology*, 2014;29(6):338-54.)

Where thread veins/telangiectasia and small blue reticular veins are being treated, small quantities of dilute sclerosant are required. Excessively strong sclerosants can damage the skin or cause more thread veins to appear. For this reason, a low concentration of sclerosant is used.

Of the two sclerosants licensed in the UK, Aethoxyskerol has the least aggressive weight/weight detergent effect. Lauromacrogol/polidocanol is a 'non-ionic' detergent and has a local anaesthetic effect. It is favoured by some phlebologists in the treatment of thread veins and telangiectases because of its less aggressive weight/weight effects. It can be safely injected outside a vein at low concentrations without leading to tissue damage. Treatment is far more effective when the sclerosant is injected into the vein, but it is reassuring to know that inadvertent extra-vascular injection will not lead to any problem.

The concentration of Aethoxyskerol recommended for thread veins/telangiectasia in the European Guidelines is 0.25-0.5%. The guidelines also recommend 0.5-1.0% Aethoxysklerol for reticular veins.

Fibrovein is also licensed for the treatment of thread veins/telangiectasia at a concentration of 0.2%. The European Guidelines suggest that the concentration should be in the range 0.1-0.2% for thread veins/telangiectasia. The guidelines also recommend up to 0.5% Fibrovein

for reticular veins.

Very little comparative data has been published although one study found similar efficacy of both drugs (Rao J, Wildemore JK, Goldman MP. *Dermatol Surg.* 2005; 31(6):631-5).

In general, Fibroven has a stronger weight/weight effect than Aethoxysklerol because it is an anionic (strong) detergent. For this reason, it has to be used at a lower concentration than Aethoxysklerol in the management of telangiectasia and reticular veins where excessively strong treatment may lead to adverse events such as development of fine telangiectases (telangiectatic matting) and thrombi in small veins leading to slowly-fading skin pigmentation following sclerotherapy.

In summary, both drugs are equally effective in the management of thread veins and reticular varices. Some practitioners mention that they prefer the less aggressive action of Aethoxysklerol when treating telangiectases. However, the technique used for sclerotherapy is probably more important than the drug used to perform the treatment.

No other sclerosant drug is currently licensed for marketing in the UK at the present and there are probably few or no reasons to use any other sclerosant.

In continental Europe, some practitioners use hypertonic (72%) glycerine or chromated glycerine but these are not available in the UK and appear to have little if any advantage over licensed sclerosants.

## Foam sclerotherapy for saphenous varices

Aethoxysklerol and Fibroven are licensed for use as a physician-prepared foam by mixing with air using the 'Tessari' (two syringes and a connecting tap) method.

The strength of the solution used to prepare the foam is usually 1%-3% (10 mg/mL-30 mg/mL). Foam sclerotherapy has become widely used as a sole treatment for varicose veins or as an adjunct to thermal ablation techniques such as endovenous laser ablation and radiofrequency ablation of varicose veins.

Sclerotherapy has long been used in the management of large varicose veins but was found to have limited efficacy when using 20th century methods of simply injecting the largest visible varices. We now know that the main saphenous veins, which are the source of the large varices, must be destroyed to achieve durable relief from varicose veins.

Sclerosants injected as liquids

tend to mix with blood and both sclerosants are neutralised by blood and plasma proteins. The skill of the sclerotherapist is to prevent the sclerosant mixing with the venous blood.

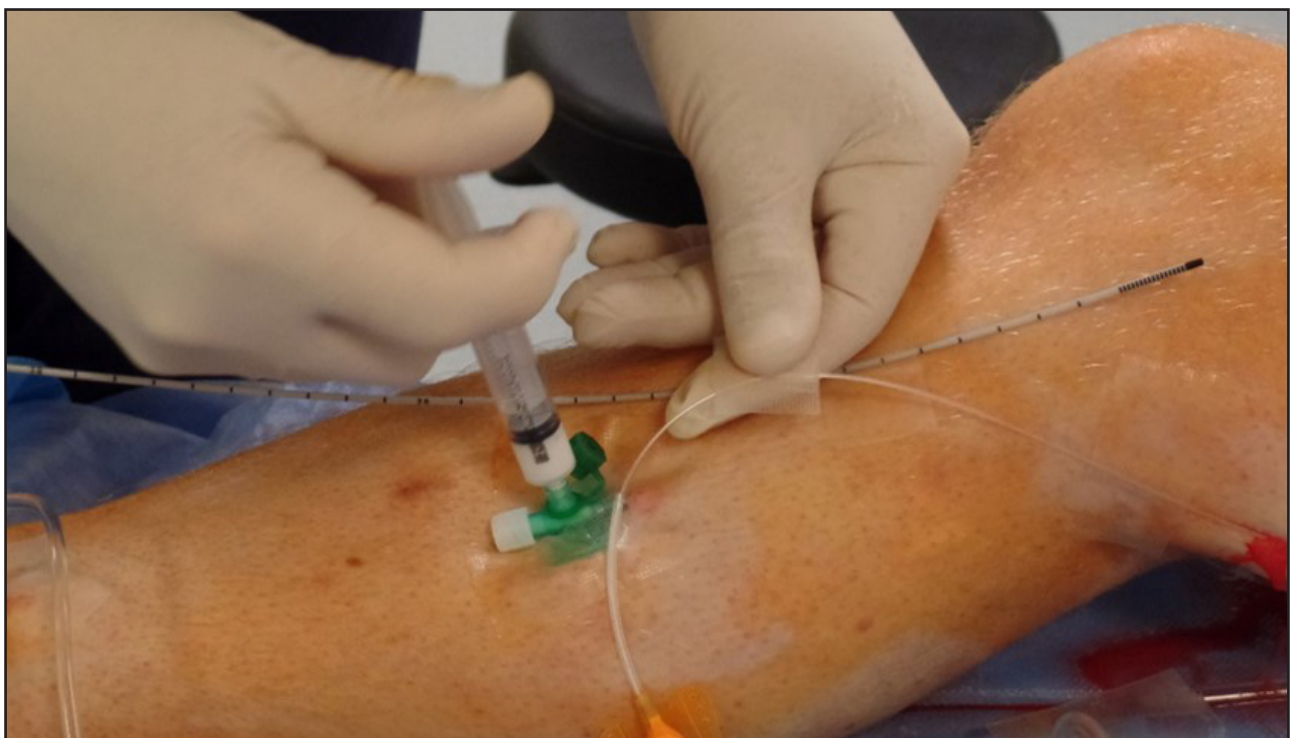
In 20th century sclerotherapy, various strategies were used to achieve this aim including elevating the leg and compressing the vein to empty it using the fingers of one hand while injecting with the other.

The 21st century technique of ultrasound-guided foam sclerotherapy minimises the mixing of blood and sclerosant because foam forms a separate phase from blood when it is injected into a vein leading to the vein being filled with the foam without contamination with blood. Using ultrasound guidance ensures that the foam reaches exactly the right veins.

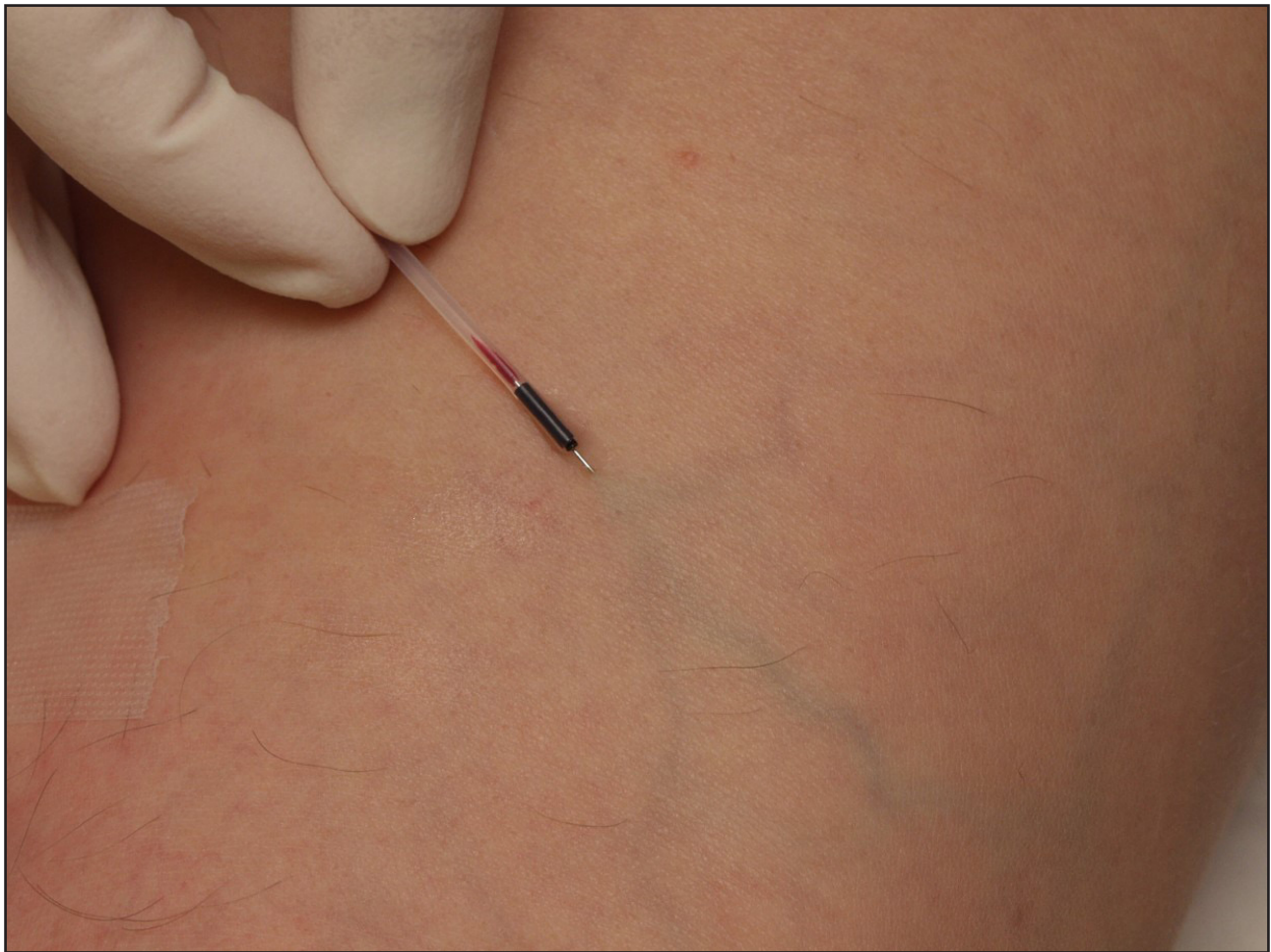Further strategies used to keep blood from the treated vein whilst the sclerosant gets to work on the vein wall include saline-flushing of the vein and injecting tumescent anaesthetic solution around the vein to compress it.

With this treatment, the most important aspect of the treatment is how it is done rather than which sclerosant is injected.

My colleagues and I developed a method of foam sclerotherapy that is



Foam sclerotherapy; image provided courtesy of Mr Philip Coleridge Smith



Reticular vein injection image provided courtesy of Mr Philip Coleridge Smith

as effective as other types of treatment in achieving durable obliteration of varicose veins.

Aethoxysklerol and Fibrovein are both effective in this treatment and are widely used to make sclerosant foam.

No detailed data comparing these two drugs for the treatment of large varices has been published.

The advantages of sclerosant foam are that the treatment requires little local anaesthetic (only at the injection sites if intravenous cannulas are used) and causes the patient little discomfort.

The disadvantage is that it is a technique that is very sensitive to the technique of the sclerotherapist. It requires experience to obtain reliable results.

Some clinical studies illustrate that a poor technique leads to unsatisfactory results with rapid recurrence of varices so proper training in the correct technique is important before undertaking foam sclerotherapy treatments.

## Adverse events

Adverse events which may arise are few.

The most serious problems with both drugs occur when allergy to the sclerosant develops. However, this is a rare event. I have only seen one anaphylactic reaction in the last 30 years, although I have also encountered three cases where skin rashes developed.

The most common problem which arises during sclerotherapy for telangiectases and reticular veins are injection ulcers. These are small regions of skin damage leading to necrosis measuring 1-5mm in diameter. They form small, painful ulcers which may become infected and take about 4 weeks to heal, leaving a small white scar.

This is an uncommon problem but one which all patients should be warned of before commencing a course of treatment.

More extensive damage to the skin may arise from the rare problem of inadvertent intra-arterial injection. This problem is largely avoided by using ultrasound guidance to inject veins but may still arise on rare occasions.

## Conclusions

The licensing of Aethoxysklerol to treat large and small varices adds a useful drug to the phlebologist's collection of treatments.

It may be used as a liquid sclerosant which is most often employed in the management of telangiectases and reticular varices.

When made into a foam using the Tessari method, Aethoxysklerol is effective in treating large varicose veins.

## Useful Resource

British Association of Sclerotherapists:  
[www.bassclerotherapy.com](http://www.bassclerotherapy.com)